

Most patients will remember when the pain and swelling began in the area of the medial aspect of the foot. This inflammatory process will lead to micro tears of the tendon. The micro tears themselves exacerbate the inflammatory process causing the tendon to become more dysfunctional and slowly lengthen, losing the mechanical strength and leading to deformity of the foot. The lack of force from the PTT causes the hindfoot to start to deviate to the side and the arch drops. Also, the heel cord starts to pull the heel to the side (Fig. B). There is also associated weakness and difficulty when standing on the tiptoes of the affected extremity. This abnormal alignment causes degenerative changes into the foot and joints that lead to arthritic pain into the foot and ankle.

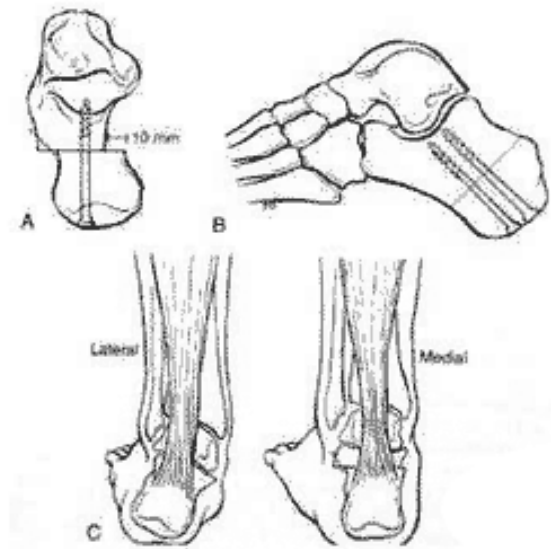


Fig.D: Medial Calcaneal Osteotomy

The diagnosis is clinical. Usually, the common presentation of the posterior tendon symptoms includes painful swelling throughout the inside of the ankle, just beneath the ankle bone. The patient will complain of weakness and difficulty walking or standing for prolonged periods of time. On observation, the patient will have loss of the longitudinal arch. He will have difficulty doing a single heel raise when standing on the affected leg. There will be a typical too many toes sign (Fig. C). The patient will also have weakness and pain on pushing towards the inside against resistance. The motion of the foot should be carefully assessed for stiffness of the joints and fixed deformities of the foot.

On X-ray, the patient will show collapse of the arch on weight bearing films and loss of alignment of the instep with the alignment of the ankle. Arthritic changes become evident with loss of joint space and loss of alignment. Other tests such as an MRI are helpful to determine the location and extent of the injury.

The treatment for PTT insufficiency depends on the amount of damage to the tendon. Conservative treatment includes rest, anti-inflammatory medications, orthosis or bracing. Occasional immobilization for a short period of time helps to decrease the symptoms. The ideal candidate for surgery will be a patient who has pain with minimal relief with rest and conservative treatment, and progressive deformity with flexible joints.

Typically, the surgical procedure consists of two major steps including repair of the tendon and realignment of the hindfoot. The ideal scenario is to reconstruct the normal resting length of the tendon primarily by adding a new tendon to strengthen the damaged tendon. Most often, a flexor tendon of the toes is harvested for this purpose.

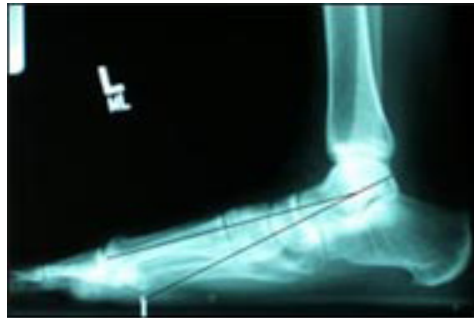

Fig.E: X-Rays of Acquired Flat Foot Deformity

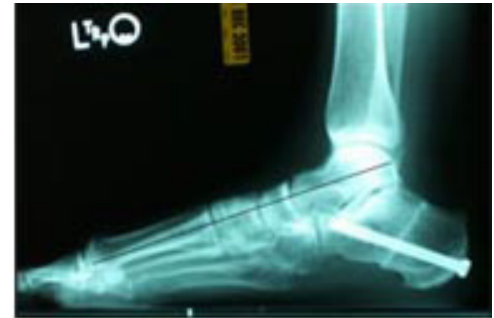

Fig.F: X-Rays After Reconstruction

The second stage of realigning the hindfoot may be done by reshaping the heel bone and moving the heel toward the inside to re-establish its position to be more closely aligned with the leg (Fig. D). Post operatively the X-rays should demonstrate restoration of the alignment of the foot (Fig. E & F).

Postoperative care consists of immobilization in a cast for six to eight weeks. Protective weight bearing is allowed at that time. Physical therapy will help recover the range of motion and strength. Most patients will require the use of an orthosis for approximately one year until they recover enough strength to do a single heel raise. At this point, the patient will be allowed to gradually increase activities as tolerated including sports activities. Most patients will continue to improve gradually over a period of two years.